Segmented Cardiac Volume Reconstruction - A Novel Reconstruction Scheme for Multislice Cardiac Spiral CT

Herbert Bruder, Karl Stierstorfer, Bernd Ohnesorge, Stefan Schaller, Thomas Flohr

Abstract—At the advent of Multislice Computed Tomography (MSCT), cardiac volume imaging is an exciting and promising tool to image the heart's anatomy and dynamics. Volume reconstruction algorithms have been implemented successfully for four slice systems allowing for retrospectively imaging the human heart in spiral scanning mode at any heart phase within the heart cycle. However, this method fails due to cone artifacts for a large number of detector slices. We present a new cardio volume reconstruction technique – called Segmented Cardio Volume Reconstruction (SCVR) – for multislice systems with a large number of detector slices. The method is characterized by computing a multitude of tilted segment images optimally fitted to the spiral path, which in a second step have to be reformatted to axial segment images and added to a complete CT image at the selected phase in the heart cycle.

Excellent image quality using a simulation study will be demonstrated for a 16 slice detector. However, we think this technique will become the method of choice in cardiac CT volume imaging for future multislice detector systems with even larger cone angles. Moreover, the method makes possible an extremely fast generation of a new volume stack for a new freely selectable heart phase by only adding the precalculated axial segment images to a complete CT image dataset. This property is extremely useful for the clinician in particular to adjust the appropiate heart phase for visualizing the coronary arteries.

Index Terms—cardiac volume imaging, spiral scanning, multislice detector

I. Introduction

Only in the recent past cardiac volume imaging with CT was boosted to high quality imaging using multislice detector technology. Whereas magnetic resonance imaging is highly effective imaging the morphology and functional dynamics of the human heart due to its excellent low contrast detectibility and its capability of diffusion imaging, CT has its domaine in detecting coronary artery disease by visualizing the coronary anatomy. Hence it can be very useful to detect stenotic malformations and in case of negative prediction avoid additional catheter study with classical angiography. Moreover, cardiac CT imaging might have the potential to detect soft plaques in an early stage of development thus providing a powerful tool to diagnose risk for infarction. Early cardiac CT techniques using prospective triggering in sequence mode are now extended by retrospective imaging methods in spiral scanning. The breakthrough of this technology came with multislice detectors in the last two years [1],[2]. Calcium scoring, for example, thus becomes a reliable and efficient tool to predict plaque frequency and increase in the coronary arteries [3].

Cardiac volume imaging currently implemented with four slice detector systems is characterized by continous data sampling and retrospective volume reconstruction of the human heart at any phase in the heart cycle. In principle the temporal resolution is adjustable. In clinical use, however, single and biphasic reconstruction using one or two heart cycles generating one dataset for a single image proved to be sufficient.

The method, however, neglects the cone angle of multislice data and hence is suitable only for a small number of detector slices. In addition, in order to generate a new volume stack for a new selectable heart phase a repeated reconstruction has to be performed for the whole image volume. These disadvantages can be overcome by using the method proposed in this paper. The basic idea is to reconstruct a set of segmented (tilted) volume stacks called booklets consisting of several booklet pages which in a second step, are reformatted to axially segmented volume stacks, and only in a third step these are temporally rebinned to a complete CT dataset for any selected heart phase selected.

II. Method

A. Short Review of Segmented Multiple Plane Reconstruction (SMPR)

In this section we will give a short description of the basics of Segmented Multiple Plane Reconstruction (SMPR) which will be presented in detail at this same conference in another presentation. This new reconstruction scheme for

H. Bruder, SIEMENS, Medical Engineering Group,
Siemenstr. 1, 91301 Forchheim, Germany,
Phone: +49-9191-188793
Fax: +49-9191-189996
e-mail: herbert.bruder@med.siemens.de

multislice spiral CT is based on the idea that the spiral focus path can be decomposed into small, overlapping segments s_0. One turn of the spiral is divided into N_{seg} subsegments. In each of these segments a stack of image pages $I_{s0,t}(x,y)$ called booklet are defined ($1 \leq t \leq N_{tilt}$; N_{tilt} denotes the number of booklet pages, which should at least equal the number of detector slices). The image pages are tilted in two directions in order to optimally fit the spiral path and to optimally use the multislice detector data. For each of these pages a set of x-rays is identified to be used for convolution and conventional 2D-backprojection. Due to the tilt of the segment pages the foci associated with these x-rays are very close to the corresponding page, thus largely avoiding cone artifacts. We use the parallel geometry in order to employ a 2D- Fourier backprojection algorithm for image reconstruction.

B. Extension of SMPR for Segmented Cardio Volume Imaging (SCVR)

1) Volume reformatting

After 2D-backprojection a set of image pages for each segment booklet is generated which for themselves do not represent CT images, because only a small number of projections according to the length of the predefined segments are utilized for each 2D-backprojection.

In a first step this stack of tilted booklet pages has to be reformatted to axial segment images located at different image positions z_{img}. This is required because the x-rays used for each separate backprojection are adapted to tilted booklet pages. An axial segment page I_{so}^{zimg} at z-position z_{img} is calculated using the following equation:

$$I_{so}^{zimg}(x,y) = \frac{1}{H(x,y)} \cdot \sum_t h\left(\left|z_t(x,y) - z_{img}\right|\right) \cdot I_{s0,t}(x,y) \quad (1)$$

The weighting function h controls the reconstruction slice-width, H represents the sum of all weights and $z_t(x,y)$ denotes the pixel-dependent z-position of the booklet page $I_{s0,t}(x,y)$.

After reformation a stack of segmented axial booklet pages is generated, which for themselves still do not represent complete CT images. Most importantly, each reformattet segment booklet corresponds to a time coordinate of the simultaneously recorded ECG, thus a phase consistent formation of complete CT images is possible as described in the next section.

2) Temporal rebinning

The volume reformation described in the previous section has to be performed for each of the segment booklets to cover the whole image volume of the heart. Thus, for each segment s_0, an image volume stack $V_{z0,s0}$ is generated. In a second step, the axial segment images of the volume stacks have to be temporally rebinned and added to complete CT images.

For this purpose a set of corresponding time coordinates $T_{0,n}$ are extracted in each heart cycle of the patient's ECG, which has been recorded simultaneously to the scanning procedure ($1 \leq n \leq N$; N number of heart cycles contained in the ECG). For each z-position z_{img} we have to identify $N_{seg}/2$ axial segment images which have to complement each other to an angular range of π. Appropriate segments can be retrieved either from one heart cycle in case of single phase rebinning or from a multitude of heart cycles in case of multiphasic rebinning. In principle, using a multitude of heart cycles for temporal rebinning provides adjustable temporal resolution.

However, in this study we restrict ourselves to single and biphasic rebinning algorithms, respectively (Fig 2). For a scanner rotation time of T_{rot}=0.5s which is provided by almost all advanced commercial scanners thus we get a temporal resolution of at least 250 ms, which in case of biphasic rebinning is even superior. We present an algorithm which automatically decides whether single phase or biphasic rebinning is used. The rebinning mode depends on the actual patient's heart rate.

In case of biphasic rebinning the CT dataset is composed of segments acquired in consecutive heart cycles. The number of segments Δs_1, retrieved from the first heart cycle is given by:

$$\Delta s_1 = floor\left(\frac{N_{seg}}{2} \cdot \left(\frac{2 \cdot T_H}{T_{rot}} - n_1\right)\right) \quad (2)$$

where

$$n_1 = floor\left(\frac{2 \cdot T_H}{T_{rot}}\right);$$

T_H denotes the length of the first heart cycle.

Hence we conclude that the single phase mode is active, if $\frac{2 \cdot T_H}{T_{rot}} - floor\left(\frac{2 \cdot T_H}{T_{rot}}\right) \geq 1$. Then $\Delta s_1 \geq N_{seg}/2$, which means that all of the segments required to complete a CT dataset to an angular range of π are retrieved from only one heart cycle.

The single phase mode is also activated at heart rates below a certain threshold depending on the pitch. The temporal resolution in case of biphasic rebinning is given by

$$\Delta T_{img} = \frac{T_{rot}}{2} \cdot \frac{\max(\Delta s_1, \Delta s_2)}{N_{seg}/2} \quad (3)$$

where Δs_2 denotes the length of the second data sector sampled in the second heart cycle.

If a new heart phase $T_{1,n}$ is selected, the presented algorithm allows for a very fast rebinning of a new volume stack belonging to the desired heart phase by only adding other suitable axial segment images to complete a CT image. Nowadays cardiac volume imaging algorithms

repeatedly have to reconstruct a new volume stack for each change of heart phase. A fast change of heart phase, however, is very useful for adjusting the appropriate time instant to image coronary anatomy properly.

3) *Proposal for the table feed*

In order to guarantee gapless volume coverage of the heart volume it is required to adjust the table feed. The z-coverage z_V of each axial segment volume stack depends on the number of detector slices N_r and is given by:

$$z_V = f \cdot (N_r - 1) \cdot S$$

where S is the collimated slice-width and f ≤1 denotes a geometrical factor which restricts the size of the target volume due to the obliqueness of the pages in each booklet. Hence, the precise value of f also depends on the image field of view. As can be seen from fig. 2 in case of the biphasic rebinning mode the spiral feed must not exceed half of the z-coverage z_V in consecutive heart cycles. Due to the possibility of interpolating missing pages at the top or the bottom of a segment booklet this limitation can be relaxed. Putting all together, in case of the biphasic rebinning mode a maximum table feed characterized by the maximum pitch value p_{max} can be calculated (here the pitch is defined as table feed per spiral rotation divided by the collimated slice-width):

$$p_{\max} \leq \frac{T_{rot}}{T_H} \cdot (f \cdot (N_r - 1) + 1) \qquad (4)$$

In case of the single phase rebinning mode p_{max} is given by:

$$p_{\max} \leq \frac{T_{rot}}{T_H} \cdot (f \cdot (N_r - 1) + \frac{1}{2}) \qquad (5)$$

As an example: for a 16 slice detector with gantry rotation time T_{rot}=0.5s and f = 0.85 we get the following pitch values p_{max}:

60 bpm: $p_{max} \leq 6.6$ (single phase rebinning)

90 bpm: $p_{max} \leq 5.5$ (biphasic rebinning)
(bpm=beats per minute).

Using a collimated slice-width of S = 1mm the entire heart can be scanned in about 11s! even if the biphasic rebinning mode is applied. As can be derived from equation (3) the temporal resolution is in the range of 125 – 250 ms for a 0.5s rotation scanner.

III. Simulation Results

We present a simulation study based on a semi-anthropomorphic phantom of the human heart and thorax. In order to demonstrate the potential of the Segmented Cardiac Volume Reconstruction we simulated a realistic dynamic behaviour of the coronary arteries. We show axial and Multi-Planar-Reformattings (MPRs) for a 16 slice detector system.
Excellent image quality is achieved both in the single phase and biphasic rebinning mode at different heart rate (Fig 3).

IV. Conclusion

A new cardiac volume reconstruction technique, called Segmented Cardiac Volume Reconstruction (SCVR) has been presented. The method is based on an algorithm which takes into account the conical shape of projection data in multislice CT. Thus the new algorithm is well suited for multislice data with a large number of detector slices. In addition, the new algorithm allows a very fast recalculation of an image volume for a new selection of the heart phase within the heart cycle. This is a major advantage when adjusting the appropriate heart phase in order to visualize the coronary arteries. We think that SCVR will become the method of choice for cardiac imaging when larger cone angles in multislice CT, become more common place.

V. References

[1] B. Ohnesorge, T. Flohr , Ch. Becker et. al, 'Cardiac Imaging by Means of Electrocardio-graphicallly Gated Multisection Spiral CT: Initial Experience', Radiology 2000, 217:564-571

[2] H. Bruder, S. Schaller, B. Ohnesorge, T. Mertelmeier, 'High temporal resolution volume heart imaging with multirow computed tomography', SPIE Med. Imag. Conf., Vol. 3661, 1999, 420-432

[3] C. Becker , T. Kleffel, A. Crispin, A. Knez, Y. Young, U. Schoepf, R. Haberl, M. Reiser (2001). 'Coronary Artery Calcium Measurement: Agreement of Multirow Detector and Electron Beam CT' Am J Roentgenol in press.

Fig 1: Parallel projection view of a segment booklet for a 16 slice detector. For better visibility, only four of the booklet pages are shown. In addition the virtual detector located in the center of rotation (D_c) and the physical detector (D_P) are shown. It should be pointed out that a curved physical detector in fan-beam geometry will show

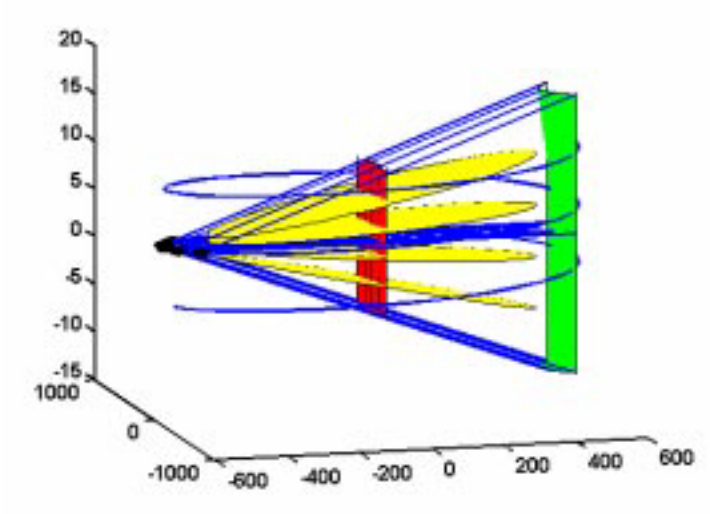

Fig 2 Principle of the Segmented Cardiac Volume Reconstruction (SCVR). The segmented volume stacks are reformatted to axial segmented volume stacks. In a second step a temporal rebinning procedure using temporal information from the patients ECG retrieves phase consistent segmented volume data and adds them to complete CT-images at the desired z-positions z_{img}. The biphasic rebinning mode is shown in the figure below.

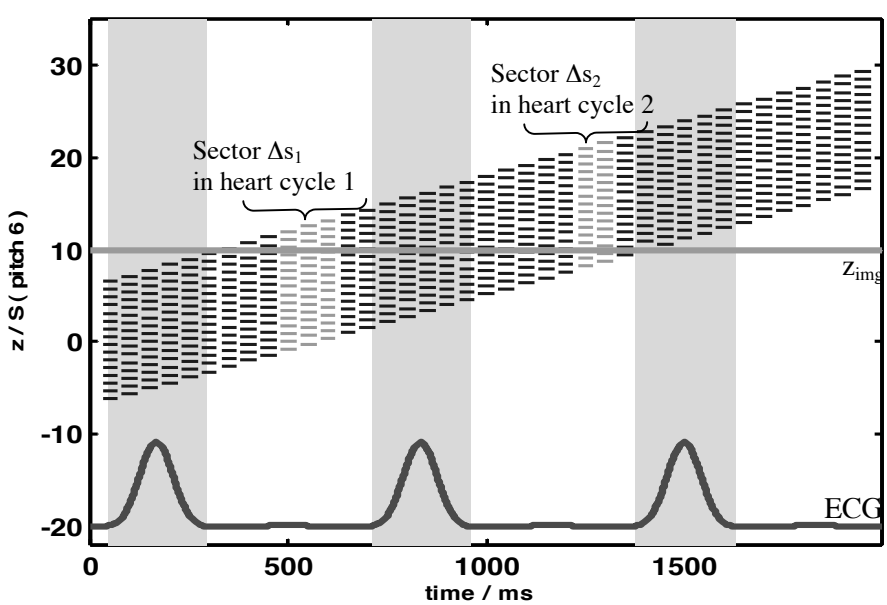

Fig 3: Oblique MPR of anthropomorphic heart phantom. A 16 slice detector with 1 mm collimated slice-width operating at pitch 6 was simulated. At a heart frequency of 90 bpm the biphasic rebinning mode was active. Both calcium and soft plaques are clearly delineated in the model of coronary artery.